

**This is NOT an interpretation of the examination.
See patient dictated report for radiologist findings & impression.**

THYROID ULTRASOUND

Patient Name: _____
ACC#: _____
MRN#: _____
DOB: _____
Ref Physician: _____

Site: _____
Tech/ext: _____
Date: _____

RT lobe: Normal Abnormal Homogenous Heterogenous Hypervascular

Comments: _____

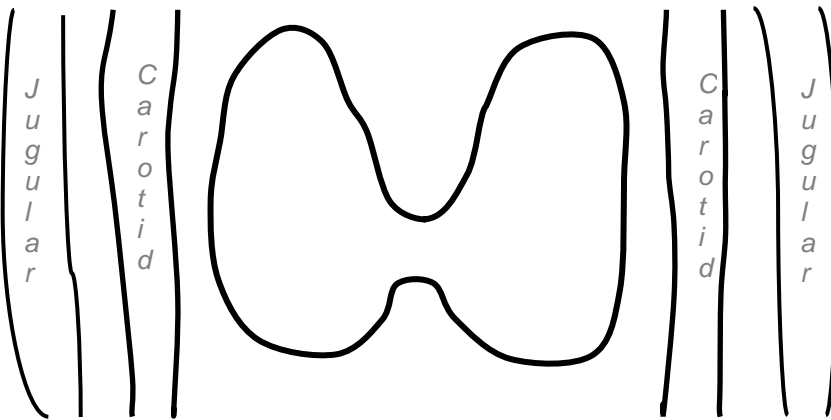
LT lobe: Normal Abnormal Homogenous Heterogenous Hypervascular

Comments: _____

Isthmus: Normal Abnormal Homogenous Heterogenous Hypervascular

Comments: _____

Neck: Normal See neck worksheet



Isthmus:

1. (CY/SP M S) (AN P/I PO) (SB IRB ETE) E.foci

New Same Changed

2. (CY/SP M S) (AN P/I PO) (SB IRB ETE) E.foci

New Same Changed

Right Lobe:

1. (CY/SP M S) (AN P/I PO) (SB IRB ETE) E.foci
 New Same Changed

2. (CY/SP M S) (AN P/I PO) (SB IRB ETE) E.foci
 New Same Changed

3. (CY/SP M S) (AN P/I PO) (SB IRB ETE) E.foci
 New Same Changed

4. (CY/SP M S) (AN P/I PO) (SB IRB ETE) E.foci
 New Same Changed

5. (CY/SP M S) (AN P/I PO) (SB IRB ETE) E.foci
 New Same Changed

Left Lobe:

1. (CY/SP M S) (AN P/I PO) (SB IRB ETE) E.foci
 New Same Changed

2. (CY/SP M S) (AN P/I PO) (SB IRB ETE) E.foci
 New Same Changed

3. (CY/SP M S) (AN P/I PO) (SB IRB ETE) E.foci
 New Same Changed

4. (CY/SP M S) (AN P/I PO) (SB IRB ETE) E.foci
 New Same Changed

5. (CY/SP SP S) (SP P/I PO) (SB IRB ETE) E.foci
 New Same Changed

Legend: (CY/SP=cystic or spongiform, M = mix solid/cystic, S = solid) (AN = anechoic, P/I = hyperechoic or isoechoic, PO = hypoechoic) (SB = Smooth Border, IRB = Irregular Border, ETE = Extrathyroidal extension) E. foci = Echogenic Foci (any calcification or echogenic foci)