

This is **NOT** an interpretation of the examination.
See patient dictated report for radiologist findings & impression.

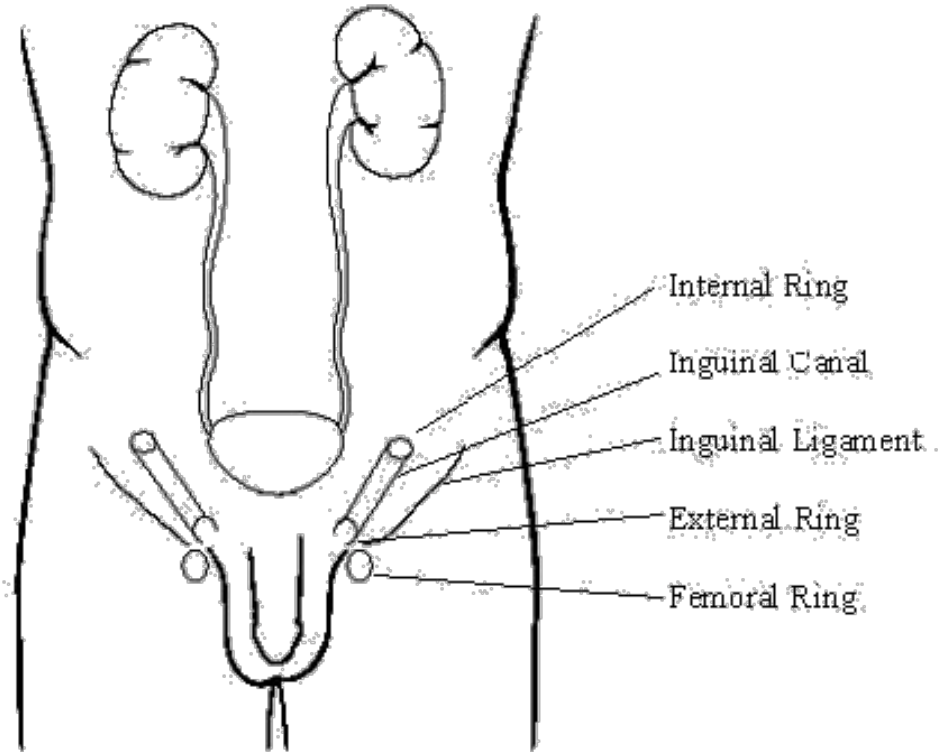
HERNIA WORKSHEET

Patient Name:	_____
ACC#:	_____
MRN#:	_____
DOB:	_____
Ref Physician:	_____

Site: _____
Tech/ext: _____
Date: _____

HERNIA TYPES:

- _____ Inguinal; passes through internal inguinal ring down inguinal canal and emerges at external ring.
- _____ Femoral; along femoral sheath in femoral canal
- _____ Spigelian hernia; along lateral edge of rectus muscle medially, cranial to junction of inferior epigastric vessels and Spigelian aponeurosis
- _____ Ventral hernia; midline



Tech Comments:
