

**This is NOT an interpretation of the examination.
See patient dictated report for radiologist findings & impression.**

Carotid Doppler

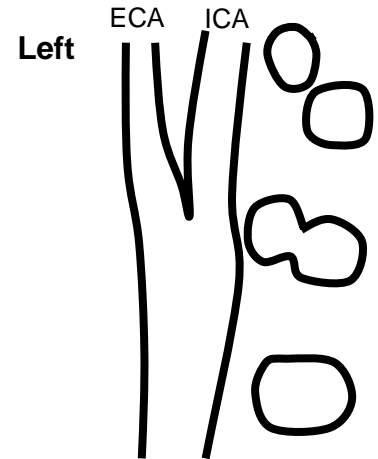
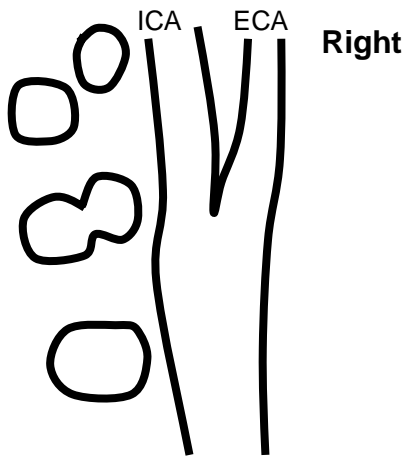
Patient Name: _____
ACC#: _____
MRN#: _____
DOB: _____
Ref Physician: _____

Site: _____
Tech/ext: _____
Date: _____

Smoker Y / N HTN Y / N Diabetic Y / N Previous Carotid Disease Y / N Heart Disease Y / N Heart Surgery Y / N

Indications: _____

% Stenosis	ICA PSV (cm/sec)	ICA EDV (cm/sec)	ICA/CCA PSV	Plaque Estimate (%)
Normal	<125	<40	<2.0	None
<50	<125	<40	<2.0	<50
50-69	125-230	40-100	2.0-4.0	≥50
≥70 but less than near occlusion	>230	>100	>4.0	≥50
Near occlusion	High, low or undetectable	Variable	Variable	Visible
Total occlusion	Undetectable	NA	NA	Visible, no detectable lumen



Right	Vertebral Arteries	Left
Ante / Retro		Ante / Retro

Surface Characteristics	
Smooth	Irregular
Plaque Characteristics	
Homogeneous	Heterogeneous

Surface Characteristics	
Smooth	Irregular
Plaque Characteristics	
Homogenous	Heterogeneous

Comments: _____