

**This is NOT an interpretation of the examination.  
See patient dictated report for radiologist findings & impression.**

## Carotid Doppler

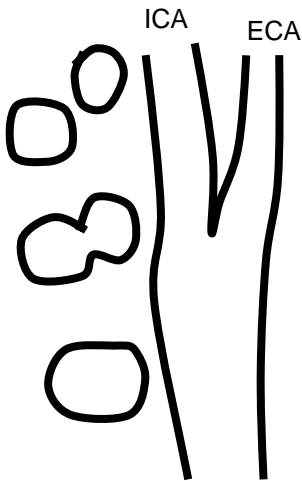
Patient Name: _____
ACC#: _____
MRN#: _____
DOB: _____
Ref Physician: _____

Site: \_\_\_\_\_  
 Tech/ext: \_\_\_\_\_  
 Date: \_\_\_\_\_

Smoker Y / N    HTN Y / N    Diabetic Y / N    Previous Carotid Disease Y / N    Heart Disease Y / N    Heart Surgery Y / N

Indications: \_\_\_\_\_

% Stenosis	ICA PSV (cm/sec)	ICA EDV (cm/sec)	ICA/CCA PSV	Plaque Estimate (%)
Normal	<125	<40	<2.0	None
<50	<125	<40	<2.0	<50
50-69	125-230	40-100	2.0-4.0	≥50
≥70 but less than near occlusion	>230	>100	>4.0	≥50
Near occlusion	High, low or undetectable	Variable	Variable	Visible
Total occlusion	Undetectable	NA	NA	Visible, no detectable lumen




RIGHT	
PSV	EDV m/s

ICA/CCA  
PSV ratio  
\_\_\_\_\_

EDV ratio  
\_\_\_\_\_

LEFT	
PSV	EDV m/s



<b>Surface Characteristics</b>
smooth                  irregular
<b>Plaque Textures</b>
homogenous          heterogeneous

ANTE/RETRO  
\_\_\_\_\_

**VERTEBRAL ARTERY**

ANTE/RETRO  
\_\_\_\_\_

<b>Surface Characteristics</b>
smooth                  irregular
<b>Plaque Textures</b>
homogenous          heterogeneous