

MRI protocol

Siemens Espree 1.5T

MRI Acceptance Criteria

- Zero patient movement while performing scan sequence
- Pad knee well in coil to prevent even slight micro motion
- Knee joint centered to FOV showing equal portions of femur and tibia

ID	Smith & Nephew	Actual
Smith & Nephew ID	116	
Pulse Sequence	tse2dl_7	
Tesla	1.5	
Scan Plane	Sagittal	
Phase Direction	F/H	
TR	6810	
TE	30-40	
Flip Angle	150	
Echo Train Length	7 or 8	
Bandwidth	199	
Concatenation	1	
% Phase FOV	100%	
Slice Thickness (mm)	2	
Slice Gap (mm)	0	
Matrix (Frequency x Phase)	512 x 256(50%)	
Fat Saturation	OFF	
FOV (mm)	22 cm	
Acquisitions	1	
Approximate Scan Time	< 10 min	
Must use 3-D correction software. Phase oversampling between 50 - 80%.		

Initial Set-up Instructions

1. Install and save the MRI sequence protocol to run for future cases as "Smith & Nephew Knee". Label 116 protocol.

Patient Positioning

1. Patient lying supine, feet first with leg in full extension and knee joint straight (up to a 15 degree bend is acceptable).
2. Restrict leg movement as much as possible, use padding and immobilization devices.
3. Knee joint centered to coil, position the coil as close to isocenter as possible.
4. Scan patient as close to isocenter as possible from left to right.

During the validation Smith & Nephew uses a specific phantom to measure the gradient linearity distortion at isocenter and maximum left position. For accuracy reasons; only a certain amount of distortion can be allowed for the VISIONAIRE process. If distortion values are higher than acceptable, then this scanner is rated Conditional for the Smith & Nephew scan. Only if the patient is scanned in the isocenter to +-30mm, (measured at the center of the knee), can it be guaranteed that the images are accurate. Please place the patient as close to isocenter as possible if scanning for VISIONAIRE. If the patient can't be placed into that position e.g. because of girth do not scan the patient and please inform the surgeon as well as your local Smith & Nephew sales representative.

Slice Positioning

See figures 1-3 for explanation of FOV centering and slice positioning. The scan must cover the entire bony knee; it is usually suggested to be 1 or 2 slices out of bone on either side. The images must be sagittal to the patient's knee in all 3 planes. Scan slices should be obliqued so that the resulting images are true sagittal, or perpendicular, to the joint line off of the coronal localizer. The slices should be obliqued off of the axial localizer so that the slices are perpendicular to a line drawn across the posterior femoral condyles. Off of the coronal localizer, the slices should be parallel to the femoral & tibial shafts.

Saving and Uploading Instructions for Test Images

1. Save DICOM files (Full DICOM format only) data to a CD directly from the MRI scanner or from PACS. Please ensure that no viewers are on this disk. Only actual scan data needs to be saved, no localizers are necessary.
2. Follow the test link in the email provided from Smith & Nephew.
3. Upload test MRI to Smith & Nephew website.

Delivering Patient Images After Site Approval

1. Your facility will receive a username and password once your site is approved.
2. Login to www.snVISIONAIRE.com. Click on the patient's name that is receiving the scans.
3. Zip all image data into one file.
4. Upload the zip file containing both the MRI and X-Ray images as described in the website tutorial.

FOV 22cm/220mm

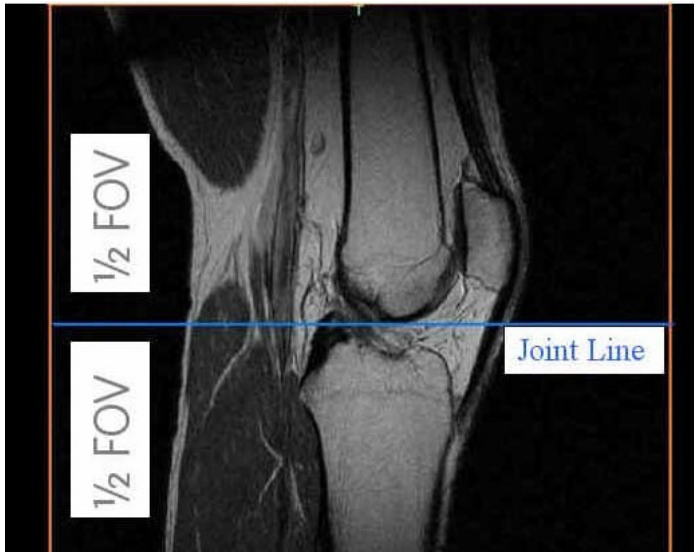

Figure 1 – Sagittal Localizer

The patient should be placed in the coil so that the resulting image has equal amounts of femoral and tibial shaft. Due to effective coil coverage some coil cut-off is expected but, this cut-off must be equally distributed and the joint space should be centered in the Field of View, (FOV). Please use sandbags, foam etc. to achieve this. This is essential to avoid patient motion on the resulting images.

FOV 22cm/220mm

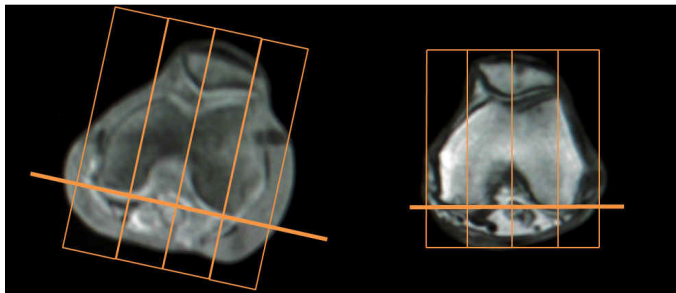


Figure 2 – Axial Localizer

The slices should be obliques off of the axial localizer so that the slices are perpendicular to a line drawn across the posterior femoral condyles.

FOV 22cm/220mm

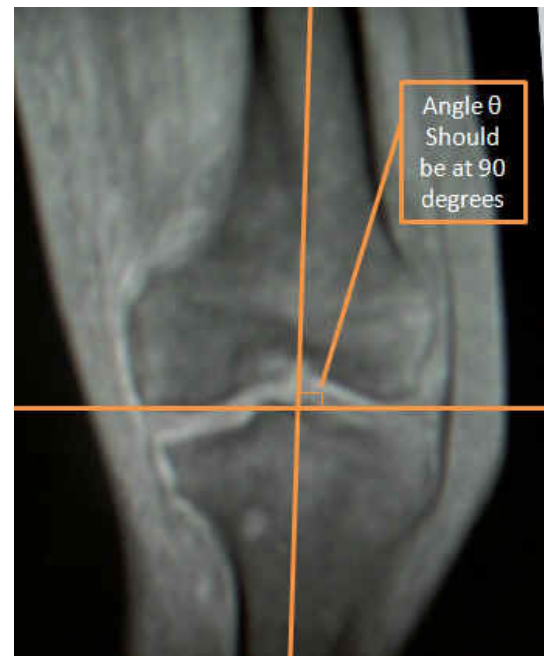

Figure 3 – Coronal Localizer

Knee joint centered to FOV showing equal portions femur and tibia. Line drawn parallel to distal femoral condyles is perpendicular to slice position. Slice coverage from R/L covers all knee bone anatomy.

Or

Draw line parallel to distal femoral condyles. Place slices 90 degrees (perpendicular) to this line.

Contact Info:

VISIONAIRE Hotline

1-800-262-3536

Option # 1

VISIONAIRESupport@smith-nephew.com

Smith & Nephew, Inc.

1450 Brooks Road
Memphis, TN 38116

www.smith-nephew.com

Telephone: 1-901-396-2121

Information: 1-800-821-5700

Orders and Inquiries: 1-800-238-7538

®Trademark Smith & Nephew