



Pediatric Fluoroscopy Protocol

Upper G.I. Single Contrast (FLPUGI)

Fluoro Time Target 2.5 Minutes

Preparation: The patient should be NPO according to their age: Nothing by Mouth prior to the exam.

*Newborn to 1 years old: 3 hours 2 years old to 5 years old: 4 hours

*6 years old to 16 years old: 8 hours

When possible: Use an anatomical marker within the primary beam to mark images with left or right marker. Do not compromise the exam if it is too difficult to maintain the marker in the images.

Anatomy Visualized: Esophagus, stomach, pylorus, duodenal bulb and duodenojejunal junction

Contrast: Newborn – 10 years old: EZ-Paque Barium Sulfate Powder Oral Suspension 96% - add water

** If the patient is still taking a bottle, the amount of barium will be equal to the normal amount of Milk/ formula given at their usual feeding time. For example: If the patient is normally given 3 oz. Of milk / formula in a single feeding, they should be given 3 oz. of barium for the exam.

***Document the amount of barium that the patient ingests, in mL.

Procedure: *Explain the procedure to the patient and parent

- Patient should start in the supine position with their head turned to the right
- Have the patient begin drinking the barium through a straw or bottle
 - Take at least 2 full barium filled esophagus images; exposed or screen capture
- Watch the stomach fill, fundus should be full prior to any emptying of the stomach.

(It is imperative to see the C-loop while the stomach is in the early stage of filling. Attempting to see the DJJ (duodenojejunal junction) in the LUQ through a barium-filled stomach may be impossible)

*Have the patient turn on to their right side or RAO (Whichever position allows the stomach to start To empty) Wait for the stomach to begin emptying.

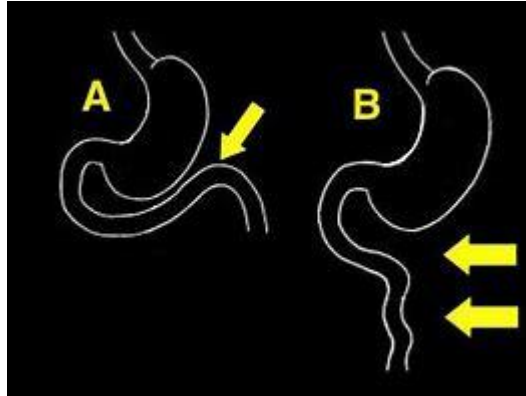
*Take at least one exposure of the duodenal bulb and C-loop filled with barium. Screen capture “Hold” images can be used to obtain any other images that might be needed.

**** (The next step and imaging of this exam are extremely important) ****

*Once the stomach empties enough, quickly turn the patient to the AP position.

- Take an image of the Duodenojejunal junction (DJJ)

(It is imperative to show, on a straight AP film, that the DJJ is to the left of the spine and at the level of the duodenal bulb. Again, it is imperative that the stomach is in the early stages of emptying to allow for visualization of the DJJ in the LUQ).



(If barium hesitates to sweep across the spine, transiently, turn the patient to their left. Always watch this process. Use gravity any time that you can to help move the barium in the desired direction. (Have the patient in the AP position; take the image of the DJJ.)

*With the patient in the right lateral or RAO position, have the patient take 1-2 swallows of the Barium.

- Take 1-2 images to document the full esophagus.

*Have the patient drink the rest of the barium. Check for reflux.

- Take an image of the esophageal/ cardiac antrum and any reflux.
- Document the total amount of barium that the patient drank and if there was reflux. Type this directly on the reflux image. Make sure this information is separated on the image as it is 2 separate pieces of information.

*If no reflux,

- Take a full view AP stomach image. Document amount of barium ingested during the procedure, on this image. Also, document, “no reflux visualized”.

***Have the Radiologist review the study before the patient leaves.**

*Care should be taken to minimize exposure to the patient and technologist.

* If aspiration is seen, consult the Radiologist before proceeding,

*Have the patient drink extra water for 2 days to reduce the chance of constipation.

(Examples of exam in PACS: *19-year-old ACC#5999520, *under 1 year old ACC#5985007)

