



Fluoroscopy Protocols  
**Retrograde Urethrogram-FLRUG**  
**Fluoro Time Target Limit- 2.0**

**\*If the patient has Medicare, this exam cannot be performed at any IDTF site (SW, RCP, and GTN).**

**\*Exam imaging goal: To image the entire length of the urethra from distal end with contrast flowing into the bladder. To visualize any strictures, leaks or other pathology.**

**Scheduling and Prep:**

- \*Male patients only
- \*There is no prep for this exam.
- \*Patient should urinate prior to the exam.

**Supplies:**

- \*Urinary catheterization tray kit
- \*20cc syringe \* Safety Needle or spike, for drawing up contrast
- \*20cc of contrast Cysto-Conray II/Omni 300 or equivalent
- \*Betadine soap \*Safety glasses \*Absorbent sheet/pad or towels
- \*Sterile gloves \*HSG catheter or Foley catheter, lubricating jelly
- \*Anatomical side marker in place
- \*13mm Tablet placed on Image Intensifier-if your machine does not have measuring capabilities built in

**Room Prep:**

- \*Place absorbent sheet on table top
- \*Prepare sterile tray
- \*Draw up contrast
- \*Flush catheter with contrast to remove air
- \*Give your patient a pair of nonsterile gloves

**Procedure:**

- \*Position anatomical marker to be visible in the images
- \*Take a scout in the AP position with Fluoro
- \*Place catheter just inside the end of the penis using sterile technique, Just enough to allow for balloon inflation.
- \*Gently inflate the balloon.
- \*Have the patient hold the catheter in place with non-superimposing hand by pinching the meatus around the catheter.

- \* Have him hold the end of his penis and catheter while elongating the Penis over the right thigh.

**SPOT IMAGES:** \*Do not use rapid imaging option  
(Scout and RPO filling, RPO post Drainage)

\*Oblique the patient's PELVIS- 45 degrees to the right. RPO

- \*Inject contrast gently and image the urethra as it fills-into the Bladder, elongate the penis over the right thigh, ensuring full Extension.
  - \*Acquire sufficient imaging of the urethra as it fills in a retrograde Fashion in the RPO position.
  - \* Demonstrate entire length of urethra. Contrast should flow into the Urinary bladder
- \*Deflate the balloon, be ready with an absorbent pad to shield you from the contrast flowing quickly out of the urethra.

\*Take one more RPO image. \* Post Drainage with the penis elongated.

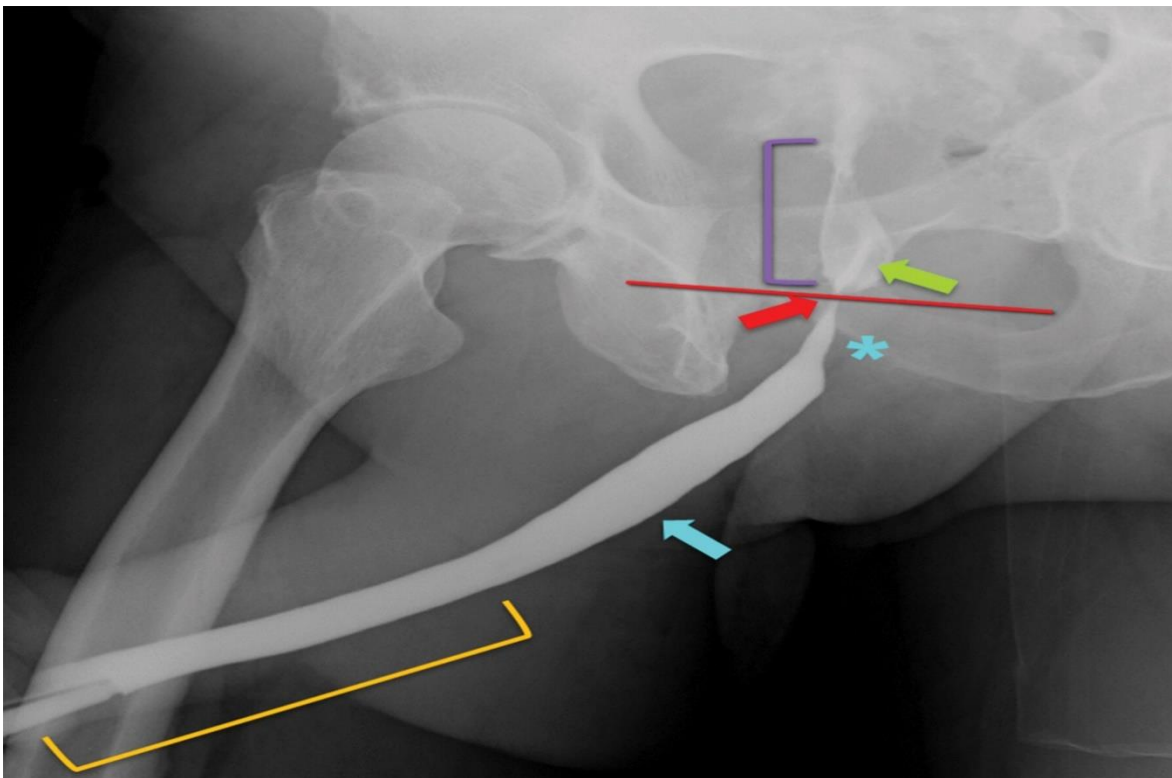
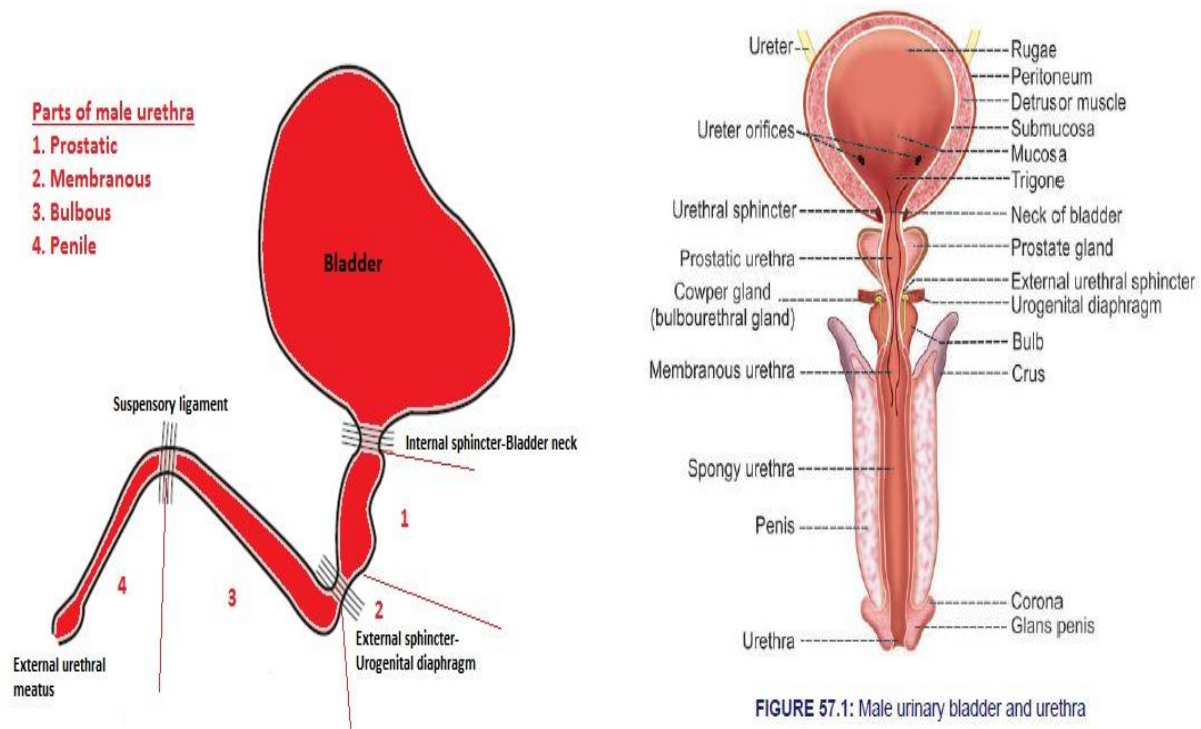


Figure 1. RUG image demonstrates normal urethral anatomy. Note the penile urethra (orange bracket), bulbar urethra (blue arrow), normal tapering of the bulbar urethra at the bulbomembranous junction (\*), membranous urethra (red arrow), urogenital diaphragm (red line), prostatic urethra (purple bracket), and verumontanum (green arrow).

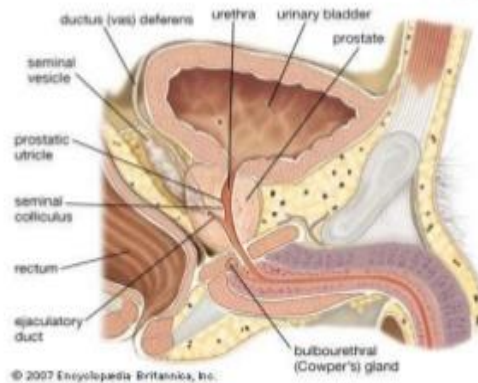
## Anatomy for Reference



## Bulbourethral Glands (Cowper's gland)

The Bulbourethral Glands are two small glands located on the sides of the urethra just below the prostate gland.

These glands produce a clear, slippery fluid that empties directly into the urethra.



- The **corpus Spongiosum** is the mass of spongy tissue surrounding the male urethra within the penis.<sup>[1]</sup> It is also called the corpus cavernosus urethrae in older texts.
- **Bulbourethral gland**, also called Cowper's gland, either of two pea-shaped glands in the male, located beneath the prostate gland at the beginning of the internal portion of the penis; they add fluids to semen during the process of ejaculation (q.v.).

\* Label your images with: scout, right, left, post drainage image.

- These are the minimum images needed to demonstrate the proper anatomy for this exam. When deemed necessary, more images may be taken to demonstrate pathology or for other reasons. Care should be taken to minimize patient and imaging team exposure.



Reviewed: January 23, 2024