



## Fluoroscopy Protocols

### **Gastric Banded- Single Contrast Barium Swallow-Adult** **FLBS**

**Fluoro Time Target Limit: 2.5 minutes**

**Scheduling and Prep:** \*There is no prep for this exam.

**Supplies:** \*Single contrast barium (L-196 or equivalent)  
\* 1-Straw and 1-drinking cup  
\*Anatomical side marker positioned on the image intensifier

\*\* For patients with a gastric band: Do not give air crystals or thick barium and do not give a barium tablet unless instructed to do so by the radiologist.

\*13 MM barium tablet (For measuring only) placed on Image Intensifier-Unless your Fluoro Equipment has built-in measuring capabilities

\*\*Obtain a Fluoro upright SCOUT image in the AP position. Center directly over the band and take a second scout to include the tubing and port. Centering over the band will give the Radiologist a true position of the band.

**Procedure:** \*Have patient in the upright position  
\*Slightly oblique the patient to the left. (This will eliminate superimposition of the Esophagus and spine)  
\*Have the patient drink one moderate sized swallow of the thin barium and watch To make sure there is not an obstruction.  
If barium does not pass through the band at all, document and show to the images to the Radiologist for instruction on whether to continue or discontinue the exam.  
  
\*If no obstruction, have patient drink several large swallows.

#### **Spot Images:**

- \*Take an adequate number of images to demonstrate the distal half of the Esophagus and band. Anticipate 4-6 images.
- \*Concentrate on the distal esophagus at the EG junction.
- \*Observe the flow of the barium through the band to determine normal restricted Flow or delayed clearing above and beyond expected restriction from the band.

#### **Procedure for Imaging the Recumbent single Contrast Esophagus:**

- \*Position the patient in the RAO position with their right arm by their side. Have

Their head on a doubled-up pillow. Have the patient hold the single contrast Barium cup with a straw in their left hand.

- \*Have the patient drink one normal sized swallow and just watch the tail of the Barium all the way down. This will show motility without gravity helping.
- \*Have the patient drink 3 large swallows fast and consecutively.

### **Spot Images:**

- \*While the patient is drinking the 3 large swallows, take spot images from superior to Inferior, 3-4, to show the entire esophagus filled with barium. **Include the barium flowing Through the band into the stomach.**
- \*Have the patient roll to the supine position and check for reflux.

➤ In order to minimize patient coughing or producing **aerosolization or Airborne Particles.**

**DO NOT:** illicit a forced cough when attempting to provoke reflux. Instead, Have the patient swallow their saliva and then tighten their stomach muscles For a few seconds. Then roll the patient enough RPO to place the barium up against The EG Junction and repeat tightening of their stomach muscles.

- \*If reflux is seen, save the image and label with “Reflux” and an up arrow.
- \*Open magnification setting and take an AP of entire barium coated structures.

**\*\*If the patient’s dysphagia symptoms are in the upper esophagus,  
Take AP and lateral 4 per second rapid imaging of the cervical esophagus.**

**\*\*Otherwise, do not take these images.**

### **Overhead Images:**

**\*\*If aspiration of the barium occurs; stop the patient from drinking, take note if the patient coughs Or does not cough. Consult with the Radiologist if he/ she feels that the exam should continue Or be discontinued.**

**\*\*The Radiologist is relying on the Fluoro technologist to witness and inform them of reflux, aspiration, stricture, pathology, and motility issues.**

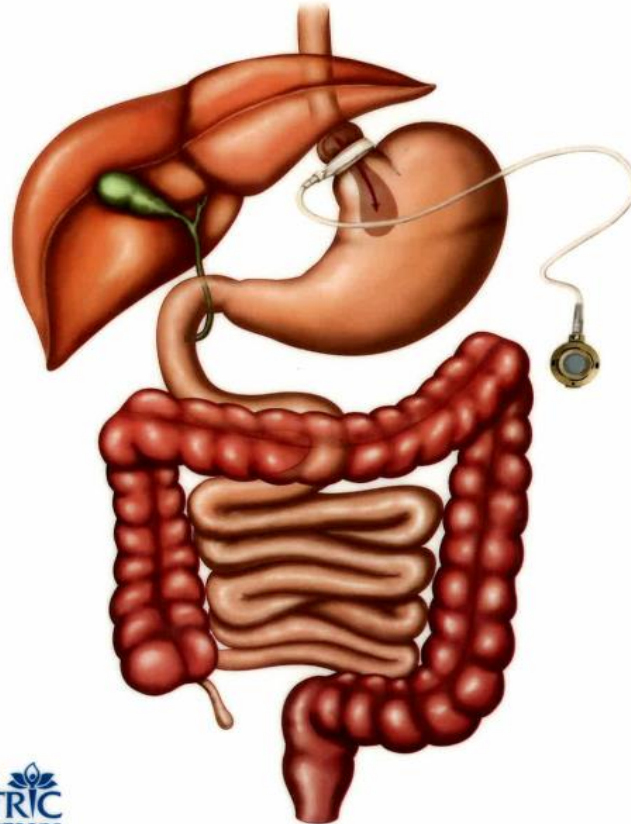
**\*\* These are the minimum images needed to demonstrate the proper anatomy for this Exam. When deemed necessary, more images may be taken.**

**\*\* Care should be taken to minimize patient and technologist exposure.**

**\*\*Following the procedure, the patient should be instructed to drink extra fluids for 2-3 Days, to help prevent constipation from the barium.**

\*\* For patients with a gastric band: Do not give air crystals or thick barium and do not give a barium tablet unless instructed to do so by the radiologist.

## Gastric Banding



Southwest  
**BARIATRIC**  
Surgeons

Reviewed January 23, 2024