



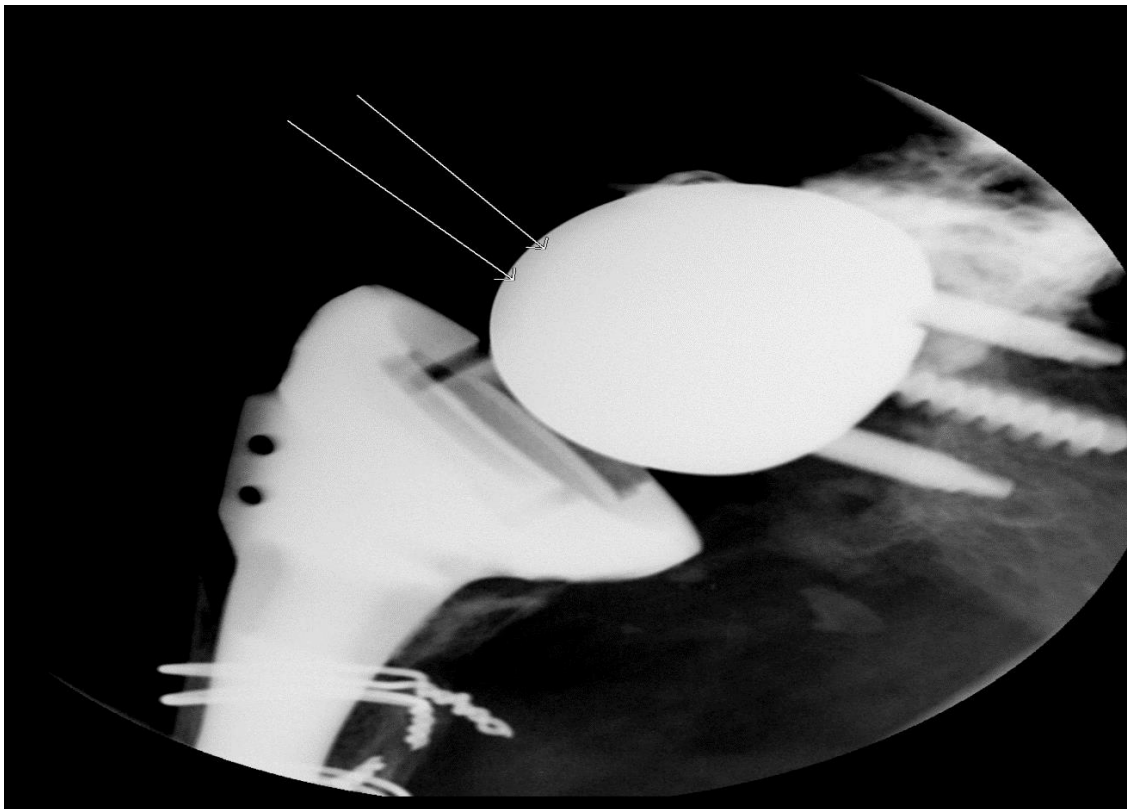
Reverse Total Shoulder Arthroplasty for CT Arthrogram

**Please contact Dr. Rodriguez for guidance if you come across a patient
With this type of shoulder replacement.**

*****If the patient has had a joint replacement, they must have a CT of the affected joint prior to the
Arthrogram with CT**

Dr. Rodriguez has provided this image to show the 2 possible spots that the needle should be placed.
See arrow points.

The needle should still be perpendicular and superior to the “V” shape between the “Ball and Socket”



1-24-2019

Reviewed April 8, 2022

Reviewed January 23, 2024